

Arthroscopic removal of impinging cement after unicompartmental knee arthroplasty

Karataglis D, Agathangelidis F, Papadopoulos P, Petsatodis G, Christodoulou A

1st Orthopaedic Department of Aristotle University of Thessaloniki

“G. Papanikolaou” General Hospital, 57010, Exohi, Thessaloniki, Greece

Abstract

Complications following unicompartmental knee arthroplasty (UKA) include aseptic loosening, polyethylene wear, arthritis progression and periprosthetic fractures. We report on a patient with a firmly fixed, sizeable cement extrusion into the posteromedial aspect of the knee after a UKA causing impingement and pain in full extension.

Cement extrusion is an extremely rare but potentially disabling complication that may occur despite care to remove all cement following implantation of the prosthesis. Removing a cement fragment, especially when this is firmly fixed to difficult-to-visualise and access parts of the prosthesis, is challenging. We believe the patient we report is the first one where a firmly fixed, sizeable cement extrusion was removed arthroscopically from the posterior aspect of the knee. This was achieved via an anterolateral portal with trans-notch view, combined with a posteromedial portal used both for viewing and instrument insertion. Arthroscopic removal of the impinging cement with the technique described above is a safe and effective option for the treatment of this difficult albeit rare problem. Hippokratia 2012; 16 (1): 508-509

Key words: unicompartmental knee arthroplasty, complications, cement extrusion, arthroscopic removal

Corresponding author: Filon Agathangelidis, 39A, Stratigou Sarafi str. 55132, Kalamaria, Thessaloniki, Greece, Tel/Fax: 00302310451195, e-mail: fagath@gmail.com

Unicompartmental knee arthroplasty (UKA) is becoming more and more popular for the treatment of patients with anteromedial osteoarthritis of the knee. Complications following UKA are rare and include aseptic loosening, polyethylene wear, periprosthetic fractures, osteoarthritis progression, infection and haemarthrosis¹⁻⁴.

Reports though of pain, restriction of knee movement and a clicking sensation related to cement extrusion are extremely rare following both conventional knee replacements and UKA⁵⁻⁹. The symptoms in these rare cases are usually caused by loose cement fragments leading to synovitis. The removal of these fragments, either by open arthrotomy or arthroscopically, often leads to complete symptom resolution^{5,6,8,9}.

We report a patient with symptomatic posteromedial cement extrusion following UKA. The extruded cement was firmly fixed to the posterolateral aspect of the tibial plate and the patient was successfully treated with arthroscopic removal in one piece of a sizeable cement piece.

Case report

A 57-year-old woman with isolated medial compartment osteoarthritis of the left knee, a pre-operative ROM of 0-105° and a correctable 5° varus deformity underwent a UKA in October 2005. A cemented Oxford UKA (Biomet, Swindon, UK) was used.

The postoperative period was uneventful and the pa-

tient mobilised partial weight-bearing with crutches on day one and was discharged from hospital after 48 hours. Six weeks post-op, the patient reported relief from medial knee pain, but complained of a sharp pain in the posterior aspect of the knee during full active knee extension. Clinical examination revealed tenderness on palpation of the medial aspect of the popliteal fossa, while pain could be elicited in this area during the final 5-10° of active and to a lesser extent passive extension of the knee. There were no clinical indications of infection and FBC, ESR and CRP were all within normal limits. X-rays revealed a radio-opaque shadow in the posterior aspect of the tibial component that appeared like cement extrusion (Figure 1).

Initial treatment with anti-inflammatory medication and physiotherapy led to significant pain subsidence for a period of eleven months. At that time the pain relapsed with the same characteristics. Another course of physiotherapy and anti-inflammatory medication was advised and the patient was again relieved from her symptoms for a short period of time. Twenty months postoperatively the symptoms relapsed once more and decision was made to proceed with a knee arthroscopy with a view to remove the impinging cement extrusion and address any other potential source of pain¹⁰.

Following a standard diagnostic arthroscopy the arthroscope was switched to the anteromedial portal and

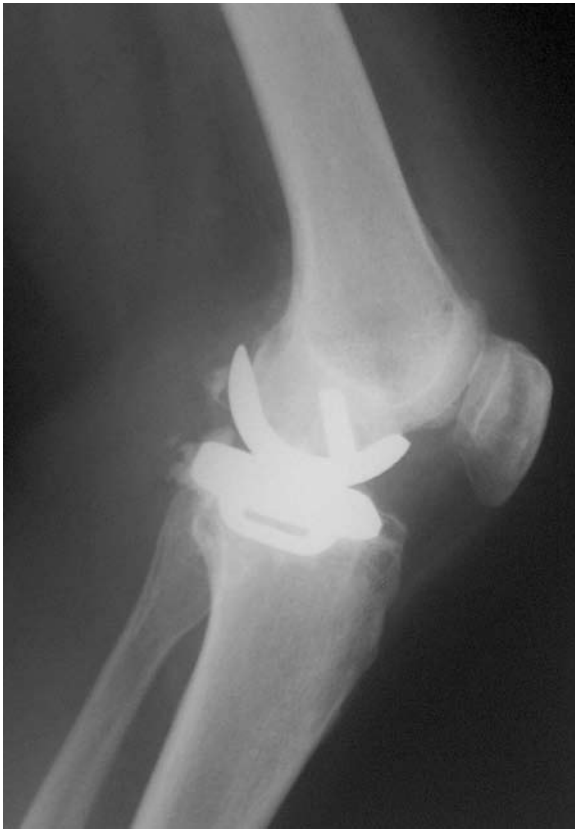

Figure 1: Lateral x-ray of unicompartmental knee arthroplasty with posterior cement extrusion.

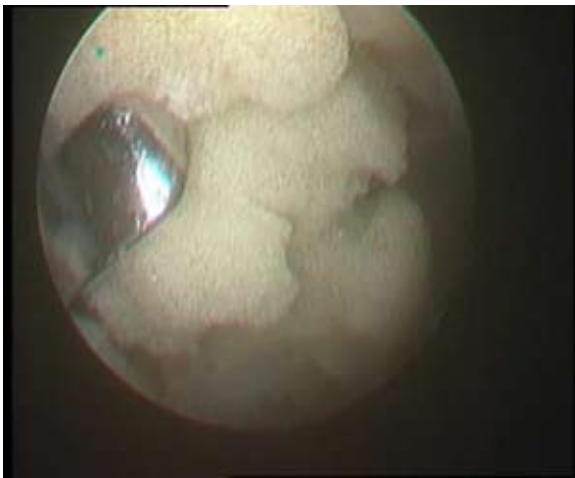

Figure 3: Cement fragment during arthroscopic removal after being broken off.

a switching stick was inserted through the anterolateral portal and was guided under direct vision between the ACL and the prosthesis to the posteromedial aspect of the knee. Subsequently, the arthroscope was advanced to the posteromedial compartment of the knee with the rail-road technique, in order to inspect it, safely establish a posteromedial portal and introduce a working cannula. Direct visualisation and detailed evaluation of the size and

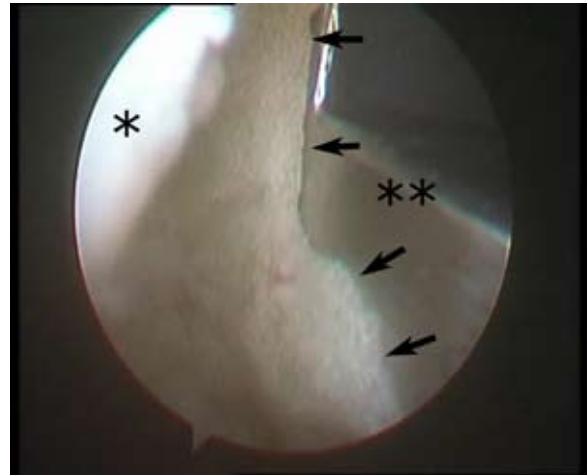


Figure 2: Arthroscopic appearance of extruded cement piece, firmly fixed to the infero-postero-lateral aspect of the tibial component (scope in the posteromedial portal). Asterisk (*) marking posterior capsule. Double asterisk (**) marking posterior aspect of tibial plate. Arrows marking cement extrusion firmly attached to the tibial plate.

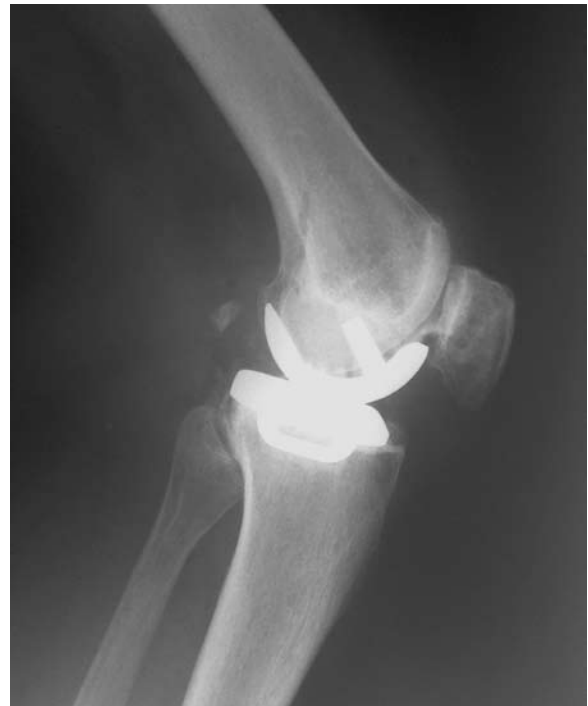

Figure 4: Lateral x-rays of unicompartmental knee arthroplasty following cement removal.

exact location of the cement extrusion was achieved with the arthroscope in the posteromedial portal. A sizeable cement piece, firmly fixed to the infero-postero-lateral aspect of the tibial component and extending laterally to the posterior septum was clearly seen (Figure 2). Despite its size it was barely seen with the arthroscope in the an-

terolateral portal. The extrusion was clearly encroaching on the posterior capsule, especially in extension, but was well away from the polyethylene and the articulating surface of the tibial plate. The cement was detached from the tibial plate with an arthroscopic elevator and sharp hammer blows and a loose-body grasper was used to remove the 2x1cm cement fragment in one piece through the posteromedial arthroscopic portal (Figure 3).

The patient was mobilised partial weight-bearing immediately post-op and progressed to full weight-bearing by the end of the first week. She reported immediate and complete relief from the sharp posterior knee pain she experienced at full extension pre-operatively. X-rays taken following arthroscopic removal of the cement extrusion showed that the previously visible radio-opaque shadow in the posterior aspect of the tibial component had disappeared (Figure 4). Twelve months post arthroscopic cement removal the patient remains pain-free with a ROM of 0-125° and an Oxford Knee Score (OKS) of 42 (improved from a pre-UKA score of 18 and a pre-cement removal score of 32).

Discussion

Compared to total knee replacement (TKR), UKA performed through a minimally invasive approach is a relatively new and rather promising option for the treatment of patients with isolated medial compartment osteoarthritis of the knee. Patient selection is made with strict criteria, including intact cruciate ligaments, minimal or no damage to the lateral compartment, correctable varus deformity and flexion deformity of <10°. However, a number of advantages including shorter hospital stay, less postoperative pain, greater range of motion and early mobilisation, make this operative option more and more popular with time.

Experience with UKA is somewhat more limited than with TKR and potential complications are still being recorded, analysed and clarified. The later are rare following UKA and include all the common complications that may be encountered after a conventional knee replacement, such as aseptic loosening, polyethylene wear, periprothetic fractures, infection and haemarthrosis. Some problems however, such as OA progression to the unreplaced compartments and polyethylene dislodgement are characteristic to UKA.

Complications and side effects related to the use of PMMA include thermal injury to the surrounding tissues, systemic effects and impingement of either loose or firmly fixed extruded pieces of cement^{5,6,8,9}. Cement extrusions occur mainly posteriorly, as cement may pass into the posterior compartment of the knee, during either tibial or femoral component pressurization^{5,9}. Technical suggestions in the attempt to avoid extrusions include cementing the femoral and tibial components separately, and trying to remove extruded cement from around the tibial plate before it sets completely with special angled instruments. However, despite care to remove all cement that may have passed into the posterior compartment of

the knee, some fragments may lodge in the soft tissues and go undetected, especially if they are firmly fixed to difficult-to-access parts of the prosthesis.

Loose, retained cement fragments may cause synovitis or, more rarely, chondral or meniscal damage in the contralateral compartment and may also generate clicking or even true locking of the knee^{5,8,9}. Firmly fixed cement extrusions on the other hand are even more infrequent, but may cause more significant problems, such as sharp pain and localised tenderness on the posterior aspect of the knee, mainly during extension, tibial nerve impingement¹¹ as well as vascular complications including haemarthrosis, venous thrombosis and even vessel erosion following long-standing cement encroachment⁷.

Cement fragment removal has been traditionally performed through an arthrotomy⁶ and this is still the case when the polyethylene needs to be changed due to cement impingement and subsequent wear. Arthroscopic removal of a cement extrusion has been recently attempted successfully in very few cases, where loose and mobile cement fragments were involved and were often removed piecemeal^{5,8,9,11}. Removing a symptomatic firmly fixed cement piece, especially when this is attached to a part of the prosthesis that is difficult to access and visualise, as was the case with our patient, may be far more challenging.

We believe the patient we report is the first one where a firmly fixed, sizeable cement extrusion causing soft-tissue impingement was removed arthroscopically from the posteromedial aspect of the knee. Moreover, this was achieved via an anterolateral portal with trans-notch view, combined with a posteromedial portal used both for viewing and instrument insertion. This portal combination offers almost full visualisation of the posterior compartment of the knee leaving few if any "blind spots"^{12,13}, which is also the case with the posterior trans-septal portal described by Ahn¹⁴⁻¹⁶. However, establishing the later has undoubtedly more potential risks due to its proximity to the delicate neurovascular structures of the region than direct establishment of the posteromedial portal⁷.

Cement extrusion is an extremely rare but potentially disabling complication that may occur despite care to remove all cement that may have passed into the posterior compartment of the knee. Removing a cement fragment, especially when this is firmly fixed to difficult-to-visualise and access parts of the prosthesis, is challenging. Arthroscopic removal of the impinging cement with the technique described above is a safe and effective option for the treatment of this difficult albeit rare problem.

No benefits in any form have been received or will be received from a commercial party related directly or indirectly to the subject of the article.

Consent for publication has been obtained by the patient.

References

1. Pandit H, Murray DW, Dodd CA, Deo S, Waite J, Goodfellow J, et al. Medial tibial plateau fracture and the Oxford unicompartment-

- mental knee. *Orthopedics*. 2007; 30: 28-31.
2. Aleto TJ, Berend ME, Ritter MA, Faris PM, Meneghini RM. Early failure of unicompartmental knee arthroplasty leading to revision. *J Arthroplasty*. 2008; 23: 159-163.
 3. Goodfellow J, O'Connor J, Murray DW. The Oxford meniscal unicompartmental knee. *J Knee Surg*. 2002;15:240-246.
 4. Maheshwari R, Kelley SP, Langkamer VG, Loveday E. Spontaneous recurrent haemarthrosis following unicompartmental knee arthroplasty and its successful treatment by coil embolisation. *Knee*. 2004; 11: 413-415.
 5. Kim WY, Shafi M, Kim YY, Kim JY, Cho YK, Han CW. Posteromedial compartment cement extrusion after unicompartmental knee arthroplasty treated by arthroscopy: a case report. *Knee Surg Sports Traumatol Arthrosc*. 2006; 14: 46-49.
 6. Otani T, Fujii K, Ozawa M, Kaechi K, Funaki K, Matsuba T, et al. Impingement after total knee arthroplasty caused by cement extrusion and proximal tibiofibular instability. *J Arthroplasty*. 1998; 13: 589-591.
 7. Langkamer VG. Local vascular complications after knee replacement: a review with illustrative case reports. *Knee*. 2001; 8: 259-264.
 8. Howe DJ, Taunton OD Jr., Engh GA. Retained cement after unicompartmental knee arthroplasty. A report of four cases. *J Bone Joint Surg Am*. 2004; 86-A: 2283-2286.
 9. Jung KA, Lee SC, Song MB. Lateral meniscus and lateral femoral condyle cartilage injury by retained cement after medial unicompartmental knee arthroplasty. *J Arthroplasty*. 2008; 23:1086-1089.
 10. Hannaoui S, Lustig S, Servien E, Ait Si Selmi T, Neyret P. [Arthroscopy of the knee after unicompartmental arthroplasty]. *Rev Chir Orthop Reparatrice Appar Mot*. 2008; 94: 678-684.
 11. Bhutta MA, Doorgakant A, Marynissen H. Tibial nerve impingement secondary to posterior cement extrusion after unicompartmental knee arthroplasty. *J Arthroplasty*. 2010; 25: 1168 e1117-1168.
 12. Morin WD, Steadman JR. Arthroscopic assessment of the posterior compartments of the knee via the intercondylar notch: the arthroscopist's field of view. *Arthroscopy*. 1993; 9: 284-290.
 13. Louisia S, Charrois O, Beaufils P. Posterior "back and forth" approach in arthroscopic surgery on the posterior knee compartments. *Arthroscopy*. 2003; 19: 321-325.
 14. Ahn JH, Ha CW. Posterior trans-septal portal for arthroscopic surgery of the knee joint. *Arthroscopy*. 2000; 16: 774-779.
 15. Ahn JH, Yoo JC, Lee SH. Arthroscopic loose-body removal in posterior compartment of the knee joint: a technical note. *Knee Surg Sports Traumatol Arthrosc*. 2007; 15: 100-106.
 16. Landsiedl F, Aigner N, Hexel M, Krasny C, Schenk S, Steinbock G. A new arthroscopic technique for revision of the posterior compartment in symptomatic total knee arthroplasty. *Arthroscopy*. 2005; 21: 506-510.